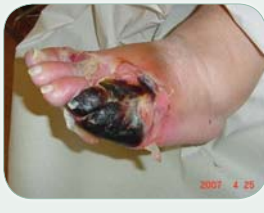
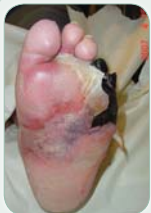
Diabetic Foot Saved From Amputation with Polymeric Membrane Dressings*

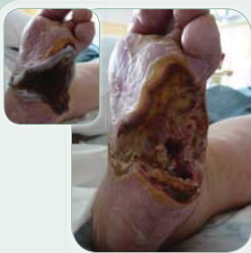Margaretha Hjalmarsson, Podiatrist
Stenbergiska Hälso Central, Lycksele, Sweden



April 2007 First visit to the foot clinic.

The wound is classified as Wagner grade 4. According to the patient it all started with a small blister on her toe a couple of weeks ago. Weak palpable pulses but no sensation present. CRP over 150. The surgeon wanted

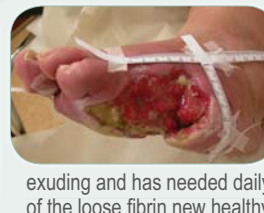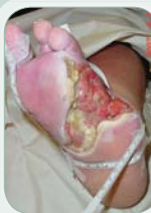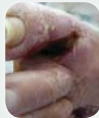the necrosis to de-mark before performing the toe amputation so the patient was sent home together with wound care instructions to the home care nurses to change the moist saline gauze twice daily. (It turned out that the nurses used hydrofiber dressings instead)



After Transmetatarsal amputation May 2007 (assessment done over the phone and internet)

Three weeks after the amputation the wound kept on deteriorating. It had been treated aily with hydrofiber dressings under the foot and a hypertonic gauze in-between the toes. The doctors were still considering foot amputation while the patient was willing to do anything to keep her foot (she had been shocked over the amount of tissue removed

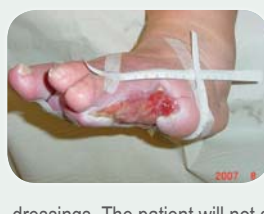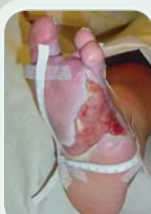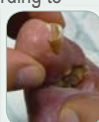during the amputation). This is when the decision was made to try the new polymeric membrane dressing as we had heard about its' cleansing and healing capabilities. Samples and instructions to the nurses were sent to the patients home.



June 2007

The first visit at the wound clinic after amputation. Prior to that we had a frequent telephone contact when I've assessed the wound with the help of photos the patient sent me via mail. The wound is heavily

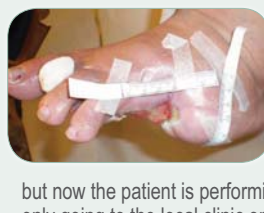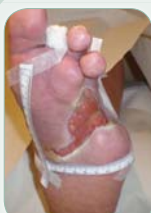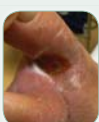exuding and has needed daily dressing changes up till now. After debridement of the loose fibrin new healthy granulation tissue is exposed. According to the patient the odour has improved a lot since she started using polymeric membrane dressings. The wound between toe 1 and 2 looks very deep and necrotic. This was the only wound she had continued to treat with hydrofiber dressings. We decided to start using polymeric membrane dressings in that cavity as well. Surgical consult confirmed good circulation with reduced sensation.



August 2007

The wound is continuously improving, new granulation tissue is formed and the open areas are getting smaller. Polymeric membrane cavity dressings are used in combination with extra absorbent polymeric membrane cover

dressings. The patient will not accept any changes to the dressing regime which has worked so well. A skin protector is used on the wound edges to prevent maceration.

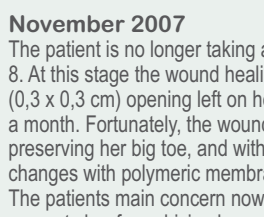
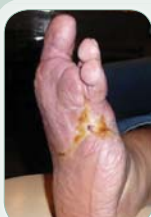

September 2007

The wound has closed 2,5 cm in one month and is becoming more superficial. The wound between toe 1 and 2 is now only 0,5 x 0,5 cm. The polymeric membrane dressings are still changed on a daily basis

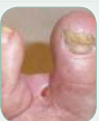but now the patient is performing many of the dressing changes herself and only going to the local clinic once a week. Most of the time she just replaces the

dressings but she sometimes needs to rinse the foot when there is dog hair embedded on the wound surface. The patient expressed her surprise over how quickly the wound is closing, the physicians had told her it would take at least 1,5 years before it closed. She is trying to off-load as much as possible but is still out walking her dogs several hours a day with her new orthopedic shoes.



November 2007

The patient is no longer taking antibiotics as the CRP has reduced to below 8. At this stage the wound healing feels very slow, there is only a small (0,3 x 0,3 cm) opening left on her foot. It has been that way for about a month. Fortunately, the wound between the toes has closed preserving her big toe, and with that, her balance. Dressing changes with polymeric membrane dressings every other day. The patients main concern now is that her deteriorating eyesight prevents her from driving her car.



Introduction

51-year-old woman with a history of congestive heart failure was forcefully taken to the ER by her daughter who felt she was overworked and pathologically tired. The diagnosis was heart failure with fluid in the lungs and diabetes with a dangerously high blood sugar level. She also had a large infected necrotic area covering more than half her left foot that the surgeons wanted to amputate.

Aim

Our primary aim was to rescue the foot from amputation, but at the same time to evaluate a polymeric membrane dressing* in regards to cleansing, absorption and healing.

Method

The patient was sent home prior to the surgical revision while waiting for the necrotic areas to become demarked. A few weeks later amputation of two toes including careful revision of necrotic area was necessary. Initially hydrofiber dressings were used. Due to wound deterioration polymeric membrane cavity and cover dressings were initiated instead. These dressings contain a wound cleanser/surfactant, super absorbent starch and glycerol, which work synergistically to draw and concentrate the body's natural healing substances into the wound bed to promote rapid healing. No extra wound cleansing is needed when using these dressings.

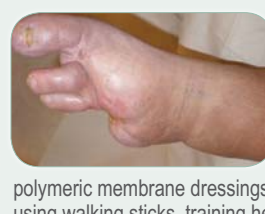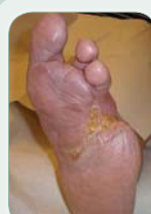Initially daily dressing changes were performed due to high amount of wound exudate, this was reduced to dressing changes 2-3 times a week as the exudate decreased.

Results

There was a dramatic improvement within a few weeks. Teamwork with professionals within the diabetic team and a very motivated patient played part in the large deep wound closing within 7 months.

Discussion

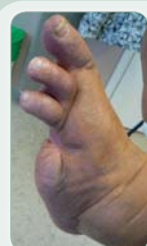Polymeric membrane dressings are very effective at absorbing large amounts of exudate. We saw a faster healing than normal with wonderful rapidly forming granulation tissue already after a few weeks use of polymeric membrane dressings. The dressings are easy to apply and remove. The patient found them much more comfortable than her previous dressings and appreciated how easy it was to change the dressings by herself. This was our first experience with polymeric membrane dressings. Since then we have it as our first hand choice for all diabetic wounds.



January 2008 8 months post amputation

The foot is completely intact. Looking back we realised how fast it closed. The skin covering the wounds is rather thin so we are still using the thinnest versions of the polymeric membrane dressings as protection and padding. The patient is now using walking sticks, training her balance with her latest orthopedic shoes.

During the entire time the patient was closely involved and motivated by her treatment. The team around her consisted of the podiatrist, dietician, diabetic nurse specialist, diabetologist, physician and nurse from cardiology and a social worker. The patient called them her angels and was convinced that they all had a part in changing her life.



February 2009

This comes from the last set of photos she sent me earlier on this year. Her letter was full of optimism and future travel plans. She was very excited and proud about having her case presented as a poster and had been helpful in providing missing photos and information during the entire process.

Bibliography

- P Vowden, RA Cooper (2006). An integrated approach to managing wound infection. European Wound Management Association (EWMA). Position Document: Management of wound infection. London: MEP Ltd, 2006, 2-6.
- Blackman, J. D., Senseng, D., Quinn, L., & Mazzone, T. (1994). Clinical evaluation of semipermeable polymeric membrane dressing for the treatment of chronic diabetic foot ulcers. *Diabetes Care*, 17(4), 322-5.
- International consensus and practical guidelines on the management and the prevention of the diabetic foot. J. Apelqvist, K. Bakker, W. H. van Houtum, M. H. Nabuurs-Franssen, N. C. Schaper *, on behalf of the International Working Group on the Diabetic Foot . PO Box 9533, 1006 GA Amsterdam, The Netherlands

*PolyMem® WIC Cavity and PolyMem® MAX Wound dressings
Manufactured by Ferris Mfg Corp, Burr Ridge, IL 60527 USA. This case study was unsponsored. Ferris Mfg. Corp. contributed to this poster design and presentation.